

Supplementary Material



Figure S1. Tapirs presenting different levels of severity of injuries in the head. (A) minor lesions, (B) moderate lesions, (C) serious lesions, and (D) severe lesions (notice the lack of the auricular pavilion).

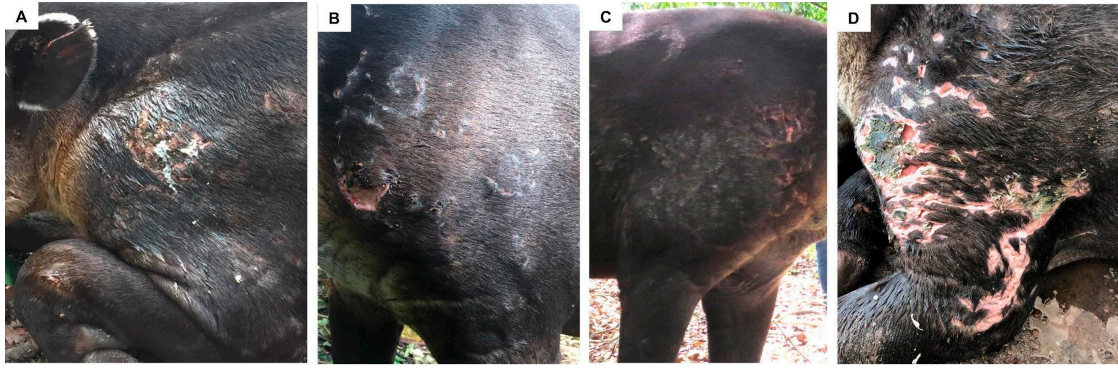


Figure S2. Tapirs presenting different levels of severity of injuries in the shoulder. (A) minor lesions, (B) moderate lesions, (C) serious lesions, and (D) critical lesions.

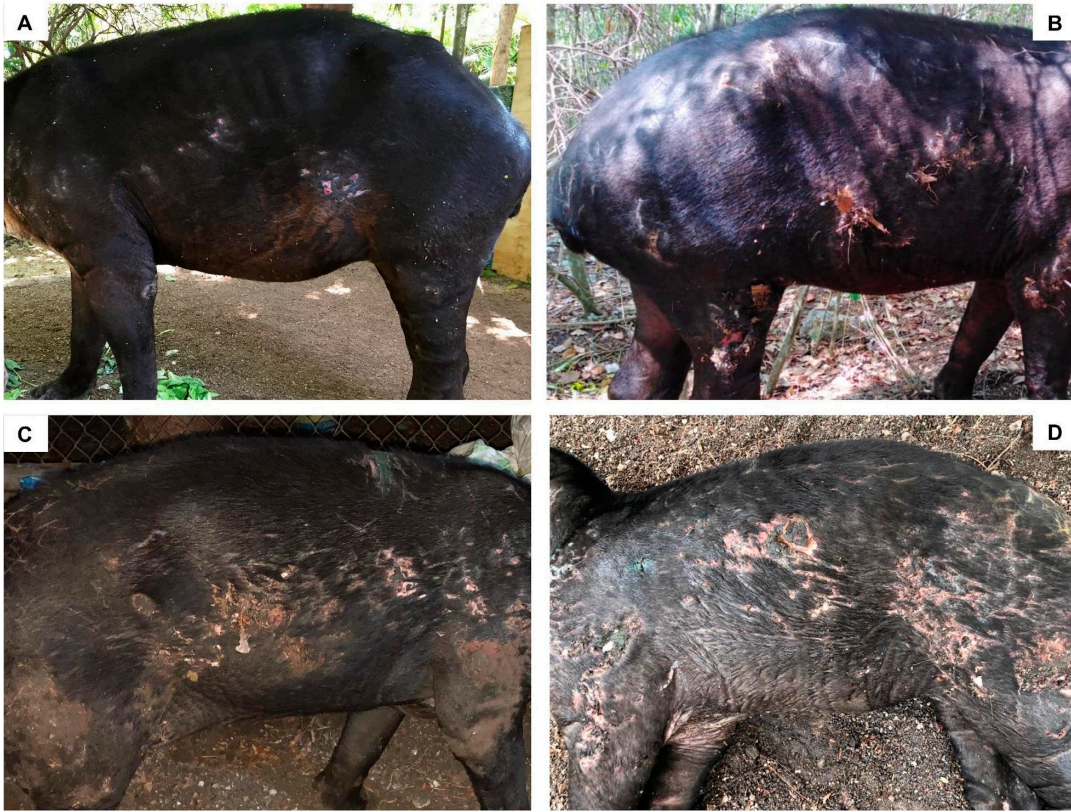

Figure S3. Tapirs presenting different levels of severity of injuries in the thorax. (A) minor lesions, (B) moderate lesions, (C) serious lesions, and (D) critical lesions.

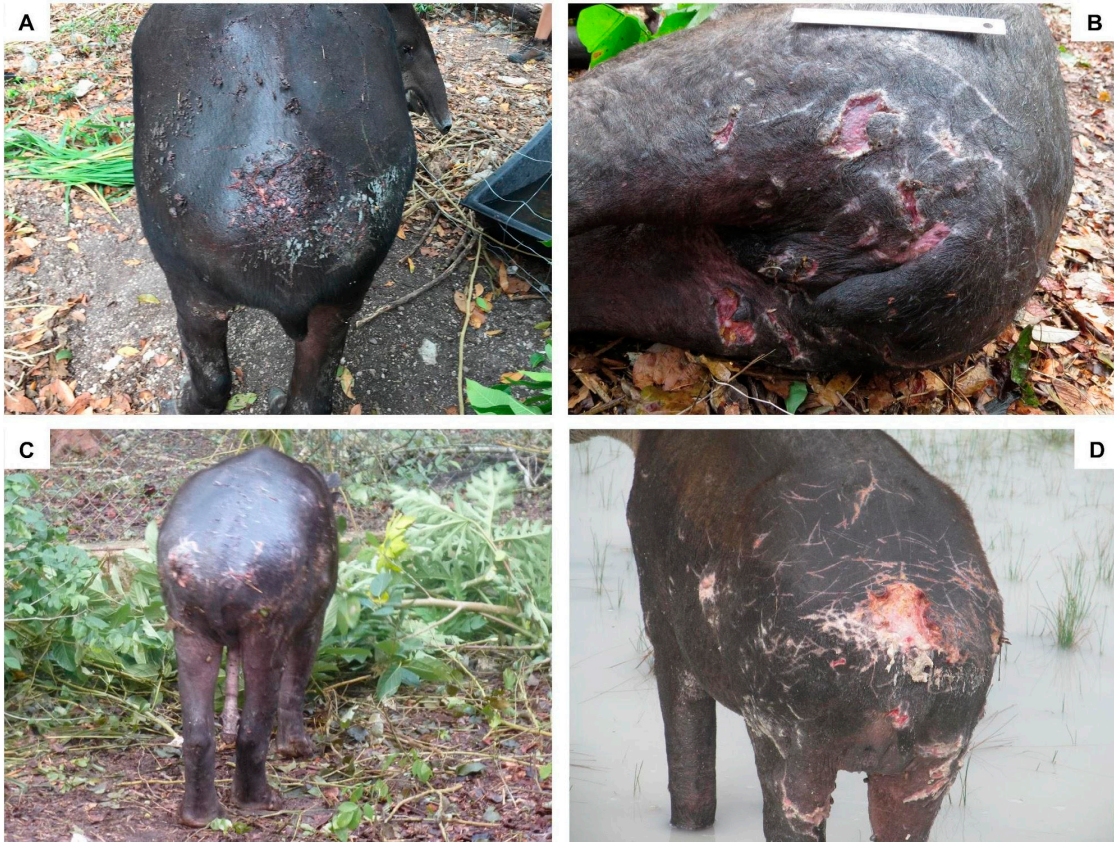

Figure S4. Tapirs presenting different levels of severity of injuries in the spine. (A) minor lesions, (B) moderate lesions, (C) serious lesions, and (D) critical lesions.

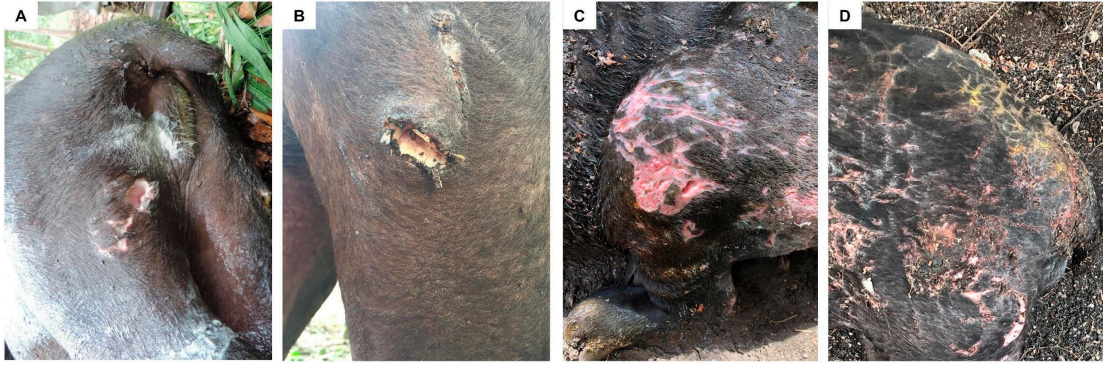

Figure S5. Tapirs presenting different levels of severity of injuries in the hind legs. (A) minor lesions, (B) moderate lesions, (C) serious lesions, and (D) severe lesions.